

**American College of Physicians - Internal Medicine Meeting 2024  
Boston, MA**

**Ophthalmoscopic Skills**

*Director:*

**Simon J. Lehtinen, MD, FACP**

**Eve Bargmann, MD**

**Anthony L. Marino, MD, FACP**

**Andrew Parsons, MD, MPH, FACP**

©2024 American College of Physicians. All rights reserved. Reproduction of presentations, or print or electronic material associated with presentations, is prohibited without written permission from the ACP.

Any use of program content, the name of a speaker and/or program title, or the name of ACP without the written consent of ACP is prohibited. For purposes of the preceding sentence, "program content" includes, but is not limited to, oral presentations, audiovisual materials used by speakers, program handouts, and/or summaries of the same. This rule applies before, after, and during the activity

**American College of Physicians  
Clinical Skills Center 2024**

**OPHTHALMOSCOPIC SKILLS FOR INTERNAL MEDICINE:  
Examination of the Undilated Eye**

**GOALS**

1. Understand the settings and functions of the direct ophthalmoscope instrument.
2. Demonstrate the proper technique of direct ophthalmoscopy and be able to observe all the chambers of the eye.
3. Recognize and identify normal ocular anatomy.
4. Recognize and identify clinical findings of common anterior and retinal pathologies.

**WORKSHOP AGENDA**

1. Ophthalmoscopic observation exercises
  - Skin & Wall
  - Positioning, Light Intensity & Aperture
  - Dot Exercise
  - Disc & Venous Pulsations
  - Physiological Cup
  - Arteries & Veins
2. Common ocular pathologies (online)

**FACULTY**

**Simon J. Lehtinen, MD, FACP, Course Director, University of Virginia School of Medicine**  
[SL4EE@uvahealth.org](mailto:SL4EE@uvahealth.org)

**Eve M. Bargmann, MD University of Virginia School of Medicine**  
[EB2D@uvahealth.org](mailto:EB2D@uvahealth.org)

**Anthony L. Marino, MD, FACP University of Virginia School of Medicine**  
[AM7HQ@uvahealth.org](mailto:AM7HQ@uvahealth.org)

**Andrew S. Parsons, MD, MPH, FACP University of Virginia School of Medicine**  
[ASP5C@uvahealth.org](mailto:ASP5C@uvahealth.org)

**DISCLAIMER:** The faculty has no financial interest in the content or devices used in this workshop.

## I. The Ophthalmoscope

The ophthalmoscope was first introduced by Hermann von Helmholtz in 1850 leading to the emergence of ophthalmology as the first organ-based specialty in medicine. Many modifications were made in succeeding decades by famous ophthalmologists, eventually resulting in the present instrument. Today's exercises will focus upon use of the standard hand held ophthalmoscope (Figure 1).

The ophthalmoscope consists of a base with a power source and a head which contains focusing lenses and aperture options. There is about a 15 times magnification between the real size of the retinal structure and that seen through the ophthalmoscope. The base contains a rechargeable battery power source with an on-off button (usually green) that also acts as a rheostat to control light intensity. Electric models are also available. Battery powered scopes have a continuous use time of two hours and frequently need to be recharged. Because of the exceptional brightness of currently used fiber optic light bulbs, it is important to dim the light intensity and use the lowest power needed to adequately visualize the retina while minimizing patient discomfort and reflective interference.

The head usually contains three light aperture size options. For undilated eye examination, the smaller or medium openings are best. A red-free lens (darkens and accentuates vascular structures) as well as a linear slit opening and a white light with cross hairs are available for special exams. The head also features a rotating wheel which contains a series of two lens types: short focal length lenses (+ diopter, black or green) and infinite focal length (– diopter, red) lenses. The positive diopter lenses are similar to a magnifying glass that allows for direct observation of the anterior structures of the eye such as the cornea, anterior chamber and lens. These lenses can also be used for magnifying and observing skin lesions.

The red labeled lenses (Helmholtz' major discovery) have comparatively very long focal lengths and are primarily used for retinal observation. These lenses depend upon the intact ocular lens of the patient to focus upon the retina. The red lens that the physician uses to best visualize the retina is unique to their own lens acuity of each eye. The lens numbers refers to the diopter power of the lenses which make-up for any uncorrected refractive error in the eye of the patient or the examiner. If either is myopic and uncorrected with glasses or contacts, the retina will be seen clearer with a red numbered lens. Whereas the choice of the + diopter (green) lens is a function of the distance of the examiner from the patient's eye, the choice of the negative (red) lens is a function of the examiners own visual acuity. Unless one has had corneal surgery, the choice of a specific lens will remain constant over ones lifetime.

## II. Technique of Ophthalmoscopy

Developing the proper examination technique is key to keen examination of the eye. It is somewhat similar to a golf swing. The better the technique, the farther and straighter the ball will go, i.e. the better you will visualize both the anterior structures and retina.



Figure 1.

### 1. Holding the Ophthalmoscope

The scope should be held with the index finger on the wheel (Figure 1). This enables the observer to focus the instrument without drawing back just to view the power of the lens. To examine the patient's right eye, the examiner should hold the scope in the right hand and look through the scope with her/his right eye. The positioning must be reversed when examining the left eye.

## III. The Examination

### 1. Physician & Patient Positioning

Both patient and doctor must be positioned comfortably! Usually it is logistically more efficient to have the patient sitting on a higher chair/stool and the doctor standing so that eye levels are similar. Also, the patient's other eye **MUST** be fixated on a distant and focal target. Otherwise, you will be chasing an eye that is roving throughout the available landscape and you will never be able to achieve sustained observations, the key to clinically useful ophthalmoscopy. Once the unexamined eye is fixated, the anatomy falls into a steady and predictable position.

The ideal position for the eye exam is one which allows the examiner's scope to be brought within a centimeter of the patient's cornea. Farther away than this, the examiner will be confronted with excessive light reflections and a narrowed field of view. The closer the 2 "pin holes" (pupils), the wider will be the examiner's visual field, resulting in less reflective interference.

To examine the right eye, place your left hand on the patient's forehead with your thumb just above the brow. This helps to steady the patient-examiner unit. Hold the scope in your right hand and look through the scope aperture with your right eye. This should be reversed in examining the left eye. It is very awkward to examine the patient's left eye by using your right eye. You may end up nose to nose and importantly, your head will block targeted fixation of the patient's right eye.

Note that in order to ideally maintain view through the pupillary aperture, you can also gently brace your hand against the patient's zygoma with your middle digit, pivoting on one of your I-P joints as you scan the fundus to avoid parallax (the problem that occurs when the examiner's line of vision is not congruent with the viewing axis of the scope and the patient's pupillary line of sight).

## 2. Light Aperture & Intensity

The light intensity is a balance between patient comfort and the amount of light necessary to view the ocular structures. The ideal light aperture size is partly governed by the patient's pupil size. Too wide a light beam will result in excessive reflection and too small a beam will limit the visual field diameter. Generally, the medium aperture size works well. Historically, a dimmer incandescent light bulb was used prior to current fiber optic lighting. This provided more than ample light intensity. For sustained eye examination, full fiberoptic intensity is unnecessary and excessively bright. It is therefore best to either turn the light down with the off-on rheostat switch, or perhaps click on the polarized lens (marked with an x-containing O).

## 3. Distance from Physician to Patient

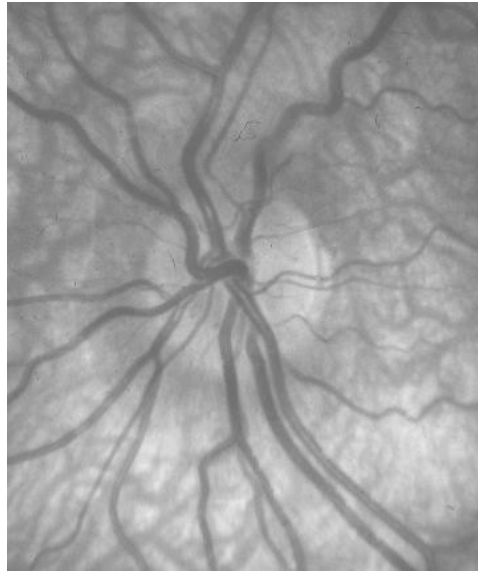In order to view the retina, the examiner's scope needs to come within 1.0 – 1.5cm of the cornea. The closer you are, the less the reflection and the greater the viewing angle you will have to view the retina. The closeness is sometimes bothersome to doctor and patient. In instructing students, we often say that "ophthalmoscopy is a contact sport" (gets a laugh). However, you do not want to touch the cornea. If the thumb of your head-holding hand is properly positioned just above the brow, it serves as a stopper and the point of contact between you and your forehead rather than upon the patient's anatomy.

## 4. Ocular Observation

Begin with directing the patient's gaze toward a localized target, straight ahead and horizontal. If you position yourself 1-2 feet from the patient and begin with a +2-3 diopter lens (black or green label) on the scope, you should see a red glow in the pupil. This represents the reflection of your light off the patient's retina (retroillumination). Any interference in this pathway of light (corneal scar, cataract, intraocular mass) will show-up within this red reflex. This is a vital part of the exam. As you then move closer to the patient's eye while keeping in place the same + diopter (green) lens, you will reach a point at which the iris image becomes sharply detailed. This represents when the focal length of your lens is perfectly congruent with the plane of the patient's iris. At this position you can now view the anterior structures of the eye under magnification such as the corneal surface, anterior chamber, iris, and even the lens (particularly if it is becoming less than crystal clear as in cataract formation).

To observe the retina, you will now need to utilize the lens (usually negative diopter, red labeled) that best fits your refractive power. Some minor lens adjustment may be necessary if the patient's visual acuity is different from yours. For example, if you and the patient are both 20/20 (neither with a refractive error), you will likely find that the "0" labeled lens provides the sharpest retinal image. For increasing degrees of myopia, higher numbered red lenses will be required. In today's workshop, we will

work through a series of exercises that are designed to help master these lens selection decisions.



**Figure 2: normal disc and cup area**

When beginning to visualize the retina, ideally you should land on the disc. To accomplish this, you must not only enter the patient's eye approximately at a horizontal level, but also approximately 15-30 degrees lateral from the anterior coronal axis of the patient. Often the first structure encountered is a vein or artery. In this case, follow the vessel towards its larger diameter or in the case of branching, follow the stem of the Y. All vessels will lead to the disc, assuming you are going in the right direction. If not, retreat and go the other way.

#### IV. Retinal Structures

1. The **optic disc** (papilla) is formed by the converging axons of the photoreceptor cells of the retina. The central retinal artery and vein are also contained within the disc and begin their systematic branching within or near the disc edges. The disc is slightly vertically oval and pinkish in color (Figure 2). A central, pale area is present within 80% of discs. This is called the **physiologic cup** and it will vary in size. You should estimate a cup/disc ratio (CDR), the diameter of the cup compared to the total disc diameter. A **cup/disc ratio** greater than 0.5 or those with notching or exaggerated vertical elongation of the disc rim are suspicious for glaucoma. Twenty percent of normal discs do not have a cup (are anatomically flat). Exaggerated sector or generalized pallor may indicate atrophy of nerve fibers, while swelling of the disc surface with blurring of the margins may indicate inflammation or papilledema.

In most patients, **venous pulsation** of the central vein or 1<sup>st</sup> vein branch can now be seen. This pulsation is best appreciated within the disc or at a sharp turn in the vein within the disc or near the disc edge. Also look for signs of pulsatile variation in the intensity of the vein redness, another observation that reveals the presence of retinal vein pulsation. Observation of ocular venous pulsations tells you that a patient's intraocular pressure is greater than intracranial pressure (secondary to compression of

the ocular vein during venous diastole), an important neurological observation that is visible in up to 90% of normal individuals. Exaggerated venous pulsations particularly in geriatric aged patients can reflect raised intraocular pressure (glaucoma).

## 2. The Retinal Vessels

Often the first structure you will observe is an artery or vein. The veins are a deeper red and larger by a 3:2 ratio than the paler-red and smaller arteries. Chronic hypertension causes sclerosis of arterioles resulting in arteriolar narrowing and often a more copper coloration. Another phenomenon of such arteriolar sclerosis is arterio-venous (A/V) nicking. This is best seen in a second or further branch artery that *crosses over* a vein outside of the optic disc. The vessels at the crossing share the same adventitia. When this contracts or thickens in chronic hypertension, the course of the vein is narrowed such that it appears the venous column is tapered (nicked) by the artery.

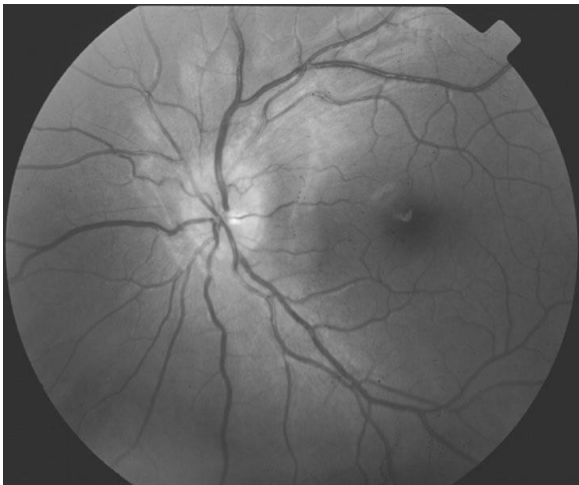

Figure 3: Normal posterior retina including macula.

## 3. The Macula

The macula lies about two disc diameters temporal to the disc. The center of the macula is the fovea. It lies just inferior to a horizontal line drawn through the center of the disc. The macula is darker than the surrounding retina because of increased pigment in the pigment epithelial layer of the retina (Figure 3). The fovea itself is devoid of retinal vasculature and receives its nutrition by diffusion from the choroid. A light reflex is often seen at the center of the fovea which is a reflection of your light off the concavity of the fovea. In order to visualize the macula and fovea, it is necessary that the patient stare directly into your ophthalmoscopic light source. This is another reason to turn your scope light intensity down to a more patient-comfortable level.

#### 4. The Peripheral Retina

Once the disc, cup, vessels and macula have been located and examined, the peripheral retina should be observed. This is best accomplished by having the patient's visual direction be held steady while you move around and survey the retinal quadrants. Sometimes it is necessary to slightly change the focusing lenses in the scope to maintain sharp clarity. It can be challenging to evaluate detail in the peripheral retinas through an undilated eye. However, gross abnormalities such as scarring, hemorrhages, exudates and retinal detachment and tumors can be easily visualized. With practice, it should be possible to obtain a view of the retina in the undilated eye up to 5 or 6 disc diameters from the center of the disc.

### Common Ocular Pathologies

(Photos available in PowerPoint slide deck: descriptions below)

#### Anterior Structures

1. Corneal abrasion: Defect of the corneal epithelium. Antibiotic prophylaxis recommended
2. Dendritic ulcer: branching fluorescein staining pattern consistent with herpes simplex infection of cornea. Urgent treatment and evaluation warranted.
3. Corneal ulcer: infection of the cornea evidenced by opacification of the cornea and associated defect of the corneal epithelium. Urgent treatment recommended.
4. Corneal foreign body: Often embedded deeply in corneal stroma requiring appropriate debridement
5. Corneal burn: chemical-based usually worse than acid. Emergent irrigation warranted.
6. Hyphema: Typically evidenced by boat-shape appearance of blood at the bottom of the anterior chamber. Urgent evaluation and treatment recommended.
7. Hypopyon: Characterized by a boat-shape appearance of white blood cells at bottom of the anterior chamber.
8. Cataract: Opacification of the lens, typically not vision or life threatening.

#### Retinal Observations

1. Arteriosclerosis: vessel caliber ratio of less than normal (3:2; Vein:Artery).
2. Diabetic Retinopathy (mild): characterized by few dot blot hemorrhages, microaneurysms, cotton wool spots.
3. Diabetic Retinopathy (severe): more dot blot hemorrhages, microaneurysms and cotton wool spots. Venous beading, disc edema, and exudates also seen.



4. Proliferative Diabetic Retinopathy: see severe diabetic retinopathy. In addition, bleeding associated with neovascularization (growth of new fine blood vessels) around disc or elsewhere. Urgent evaluation and treatment recommended especially if blood vessels can be seen growing on the iris.
5. Hypertensive Retinopathy: classic findings of a-v nicking, copper wiring of narrowed arterial vessels (less than 2 art/3 ven ratio), vessel attenuation, dot-blot hemorrhages, and disc swelling (in severe cases). Needs urgent blood pressure management.
6. Branch Retinal Artery Occlusion: Stenosis of an arterial branch. Emergent treatment and evaluation recommended. Occasionally the plaque causing the stenosis can be visualized.
7. Branch Retinal Vein Occlusion: exam findings of localized area of dot blot hemorrhages, bleeding surrounding a sector of retina.
8. Central Retinal Artery Occlusion: classic finding of cherry red spot at the fovea (red spot central with whitening of surrounding retina). Emergent treatment and evaluation recommended.
9. Central Retinal Vein Occlusion: diffuse dot and blot hemorrhages and bleeding. Can sometimes also see disc edema (see below).
10. Disc Edema: represents swollen retinal nerve fiber. Disc margin is indistinguishable.
11. Optic Disc Atrophy: pale disc, comparison of both eyes can help in determining pallor.
12. The Glaucomatous Disc: characterized by thin rim and large cup to disc ratio.
13. Retinal Tear/Detachment (RD): a horseshoe tear one of the classic findings. Needs emergent attention.
14. Temporal Arteritis: Can have similar findings of arterial occlusion and arteriosclerosis. Occasionally will present with disc edema. Can also be associated with double vision. If vision disturbance is threatening will need emergent treatment given risk of bilateral vision loss.
15. Age Related Macular Degeneration (ARMD) Dry Form: Classic yellow round spots scattered about the macular region. Slow progression of the vision loss occurring over years.
16. Age Related Macular Degeneration (ARMD) Wet Form: typified by subretinal bleeding and leakage of fluid causing devastating vision loss. Urgent treatment can save vision.



## Ophthalmoscopic Skills for Internal Medicine: Ocular Pathologies

Simon J. Lehtinen MD, FACP

[SL4EE@uvahealth.org](mailto:SL4EE@uvahealth.org)

Andrew S. Parsons, MD, MPH, FACP

[ASP5C@uvahealth.org](mailto:ASP5C@uvahealth.org)

Eve Bargmann, MD

[EB2D@uvahealth.org](mailto:EB2D@uvahealth.org)

Anthony Marino, MD, FACP

[AM7HQ@uvahealth.org](mailto:AM7HQ@uvahealth.org)

Slide Contributions: Eugene C. Corbett, Jr., MD, MACP

Department of Medicine

University of Virginia School of Medicine



1

## Disclosure of Financial Relationships

Simon J. Lehtinen, MD, FACP

Andrew S. Parsons, MD, MPH, FACP

Eve Bargmann, MD

Anthony Marino, MD, FACP

Visit any speaker's profile within the *ACP Meeting* mobile app or the meeting's web platform to view disclosure of relevant financial relationships.

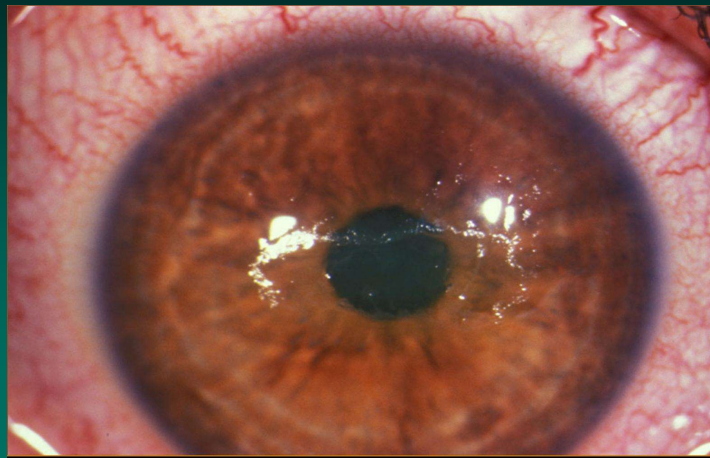


2

## Examples of Ocular Pathologies

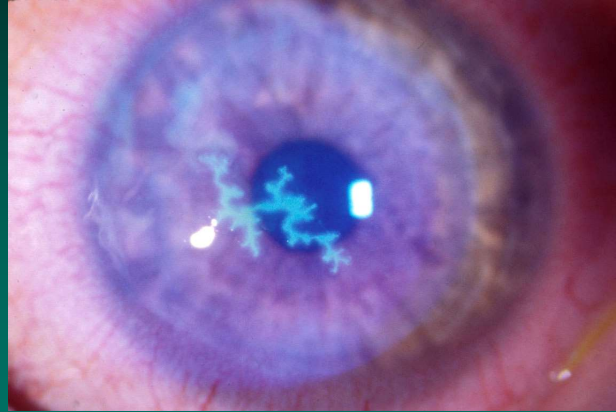
3

## Corneal Abrasion



4

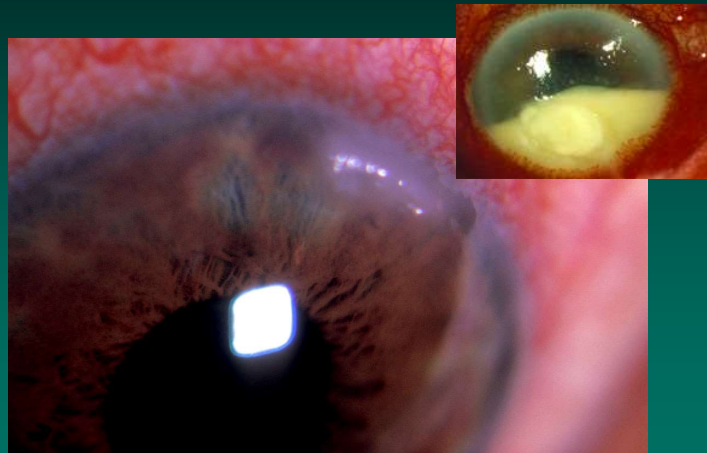
## Dendritic Ulcer



ACP  
AMERICAN COLLEGE OF PHYSICIANS  
INTERNAL MEDICINE | Doctors for Adults

5

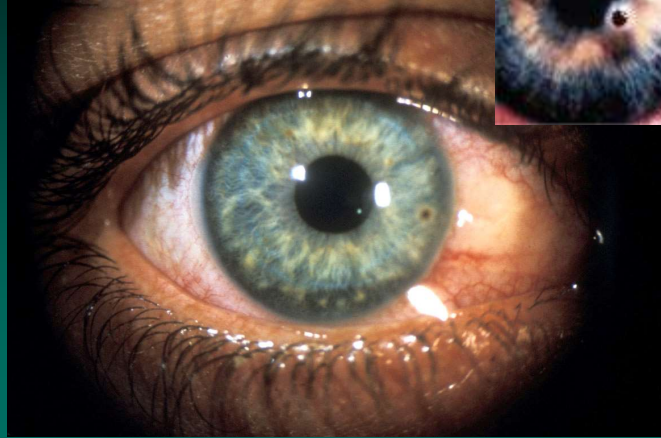## Corneal Ulcer



ACP  
AMERICAN COLLEGE OF PHYSICIANS  
INTERNAL MEDICINE | Doctors for Adults

6

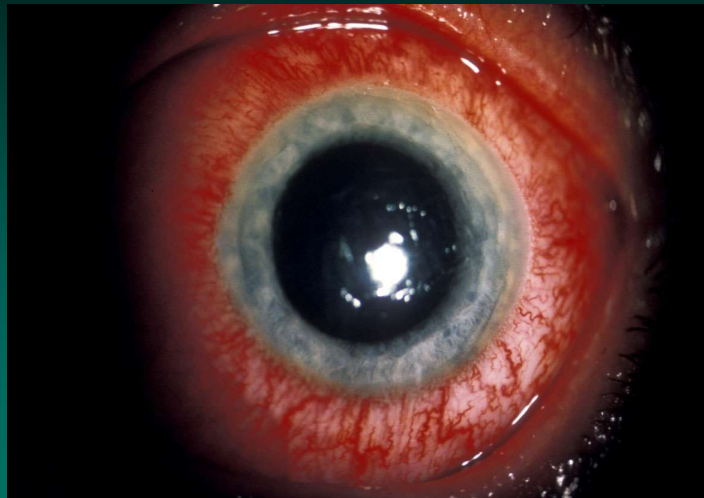
## Corneal Foreign Body



ACP  
AMERICAN COLLEGE OF PHYSICIANS  
INTERNAL MEDICINE | Doctors for Adults

7

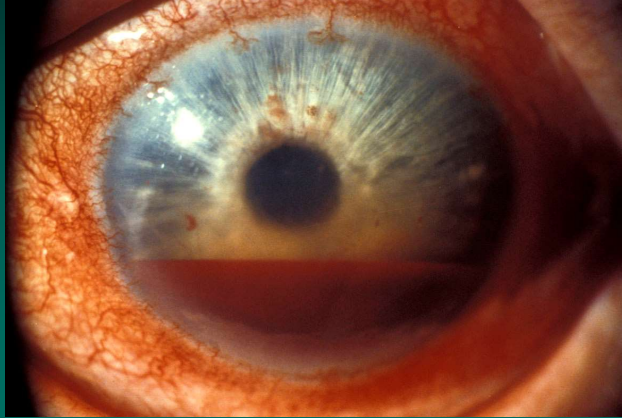
## Corneal Burn



ACP  
AMERICAN COLLEGE OF PHYSICIANS  
INTERNAL MEDICINE | Doctors for Adults

8

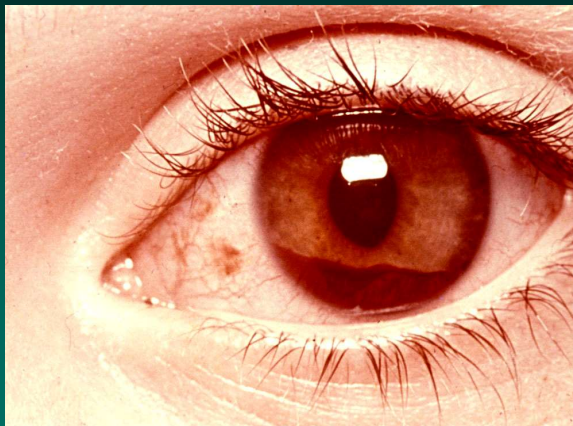
## Hyphema



ACP  
AMERICAN COLLEGE OF PHYSICIANS  
INTERNAL MEDICINE | Doctors for Adults

9

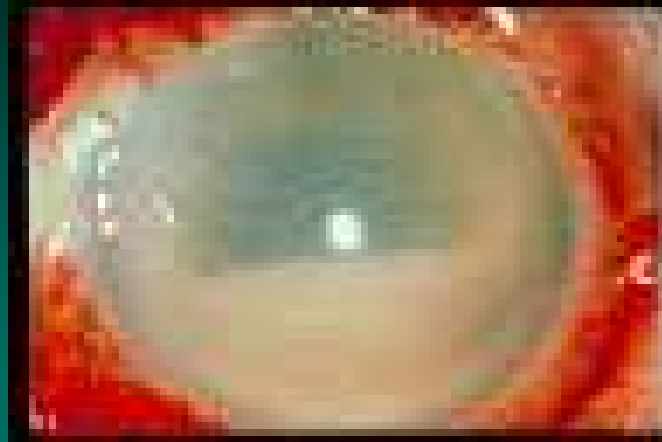
## Hyphema



ACP  
AMERICAN COLLEGE OF PHYSICIANS  
INTERNAL MEDICINE | Doctors for Adults

10

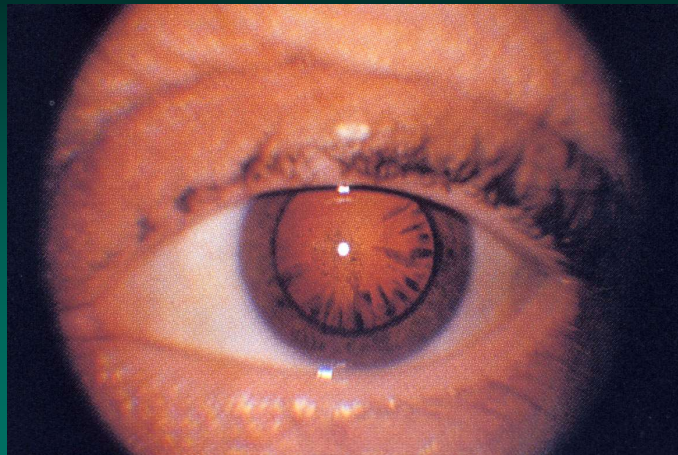
## Hypopyon



ACP  
AMERICAN COLLEGE OF PHYSICIANS  
INTERNAL MEDICINE | Doctors for Adults

11

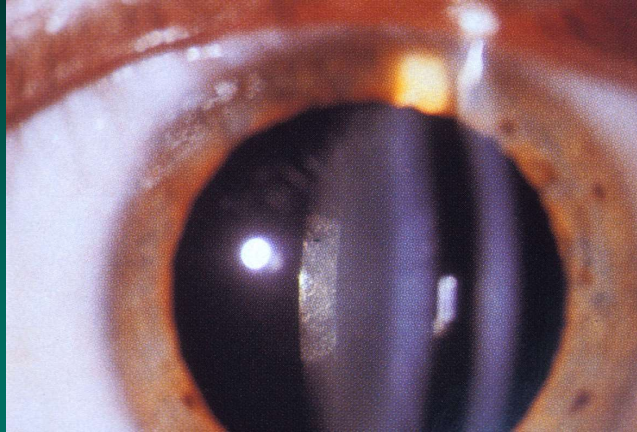
## Cortical Cataract



ACP  
AMERICAN COLLEGE OF PHYSICIANS  
INTERNAL MEDICINE | Doctors for Adults

12

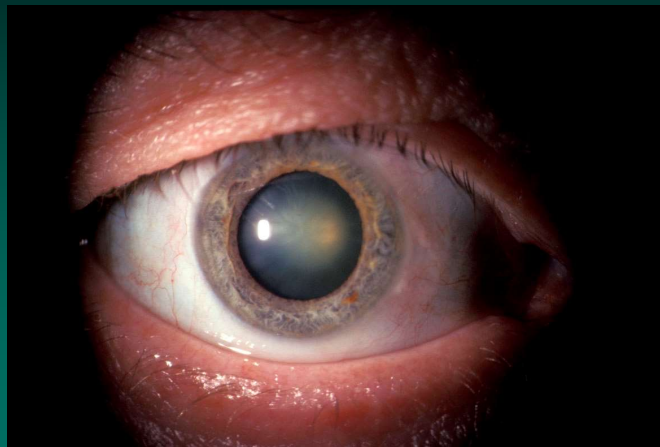## Cataract



ACP  
AMERICAN COLLEGE OF PHYSICIANS  
INTERNAL MEDICINE | Doctors for Adults

13

## Nuclear Cataract

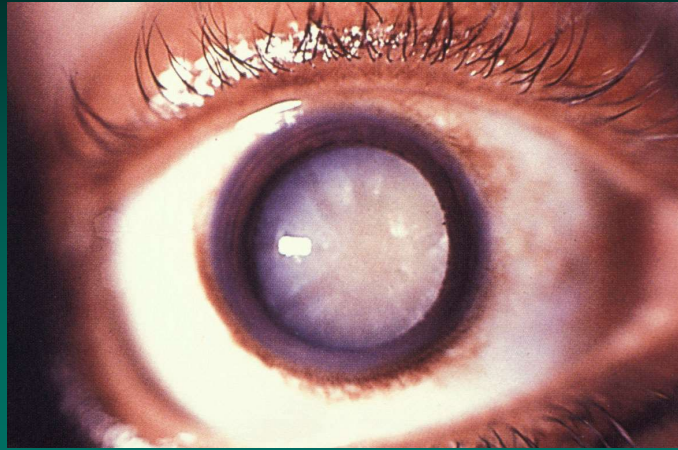


ACP  
AMERICAN COLLEGE OF PHYSICIANS  
INTERNAL MEDICINE | Doctors for Adults

14



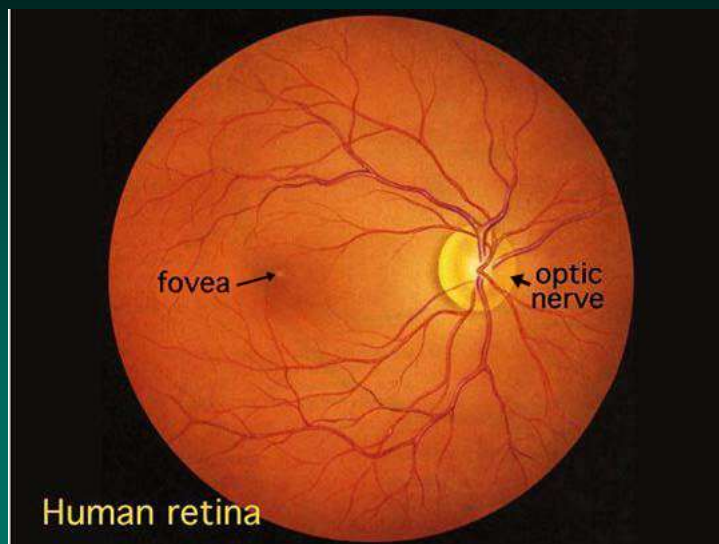
## Mature Cataract



ACP  
AMERICAN COLLEGE OF PHYSICIANS  
INTERNAL MEDICINE | Doctors for Adults

15

## Normal Retina



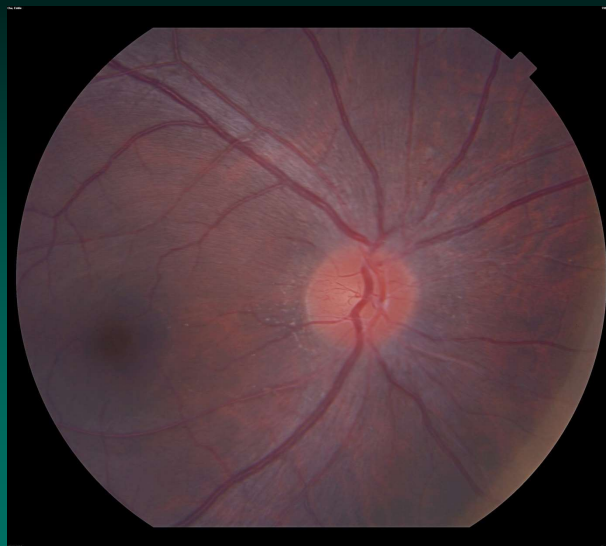ACP  
AMERICAN COLLEGE OF PHYSICIANS  
INTERNAL MEDICINE | Doctors for Adults

16

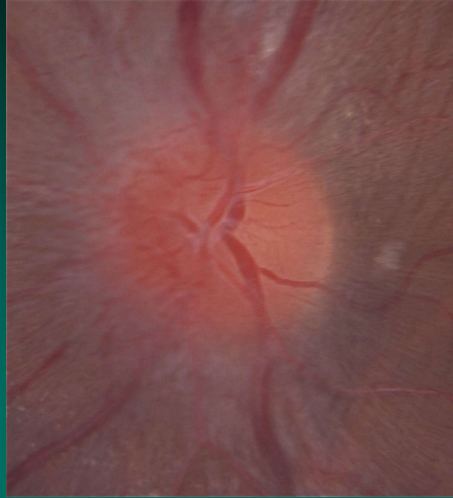
## Retinal Lesion Descriptors

- Location: o'clock relative to the disc
- Location: disc diameters from disc center
- Color
- Shape
- Size
- Above, at the level of, or below the vascular level

## Normal Retina



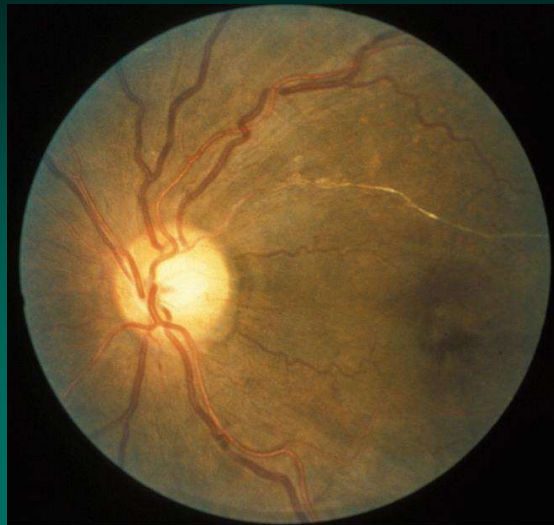**A normal margin and vessels observation.  
Often the nasal margin is slightly blurred.**



**ACP**  
AMERICAN COLLEGE OF PHYSICIANS  
INTERNAL MEDICINE | Doctors for Adults

19

**Arteriosclerosis  
Arteriolar calcification.**

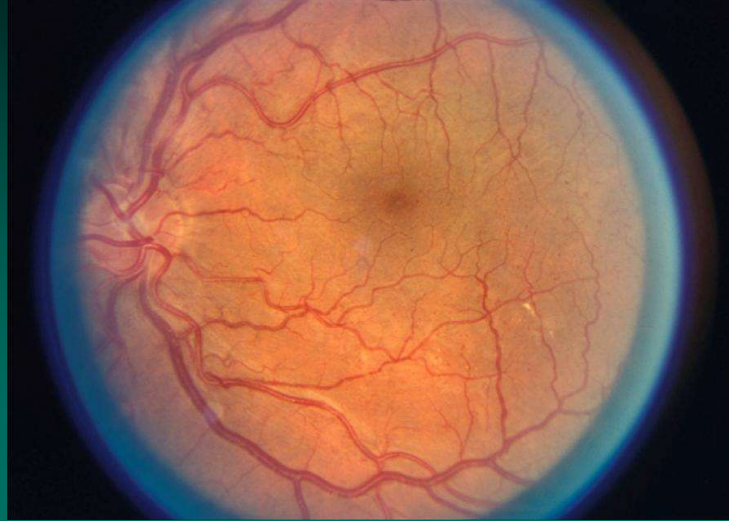


**ACP**  
AMERICAN COLLEGE OF PHYSICIANS  
INTERNAL MEDICINE | Doctors for Adults

20

## Mild Diabetic Retinopathy

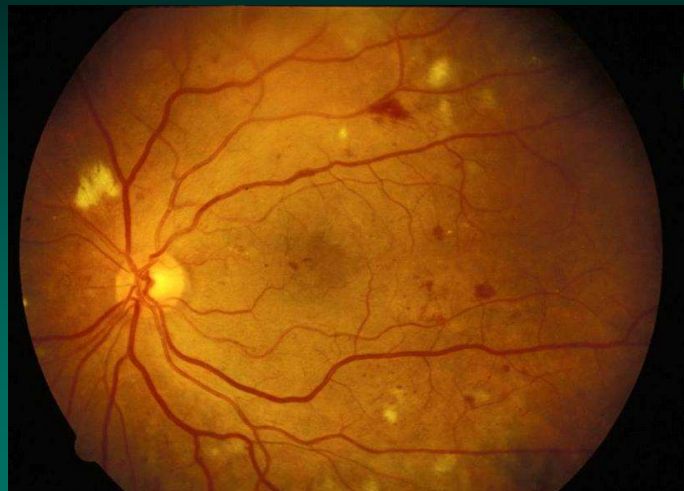
Few small exudates and microaneurysms.



ACP  
AMERICAN COLLEGE OF PHYSICIANS  
INTERNAL MEDICINE | Doctors for Adults

21

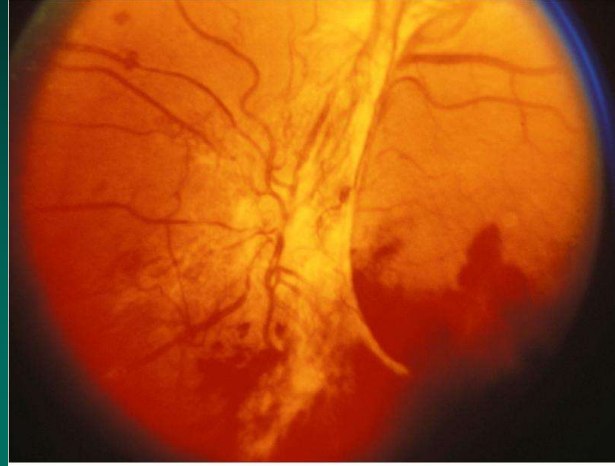
## Severe Diabetic Retinopathy



ACP  
AMERICAN COLLEGE OF PHYSICIANS  
INTERNAL MEDICINE | Doctors for Adults

22

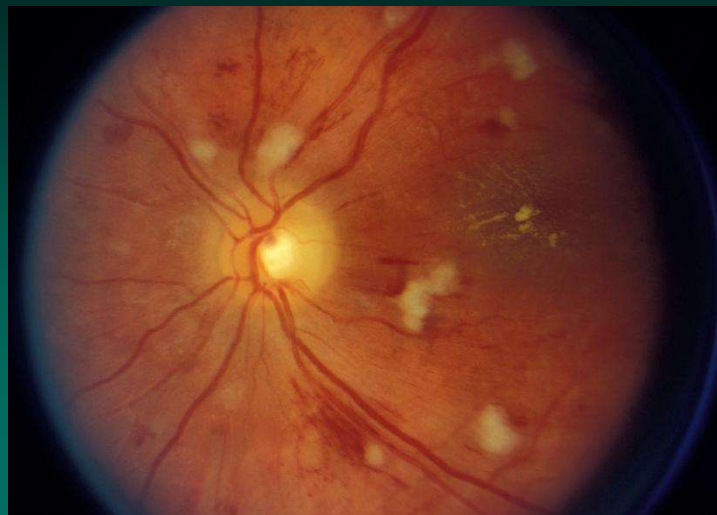
## Proliferative Diabetic Retinopathy



ACP  
AMERICAN COLLEGE OF PHYSICIANS  
INTERNAL MEDICINE | Doctors for Adults

23

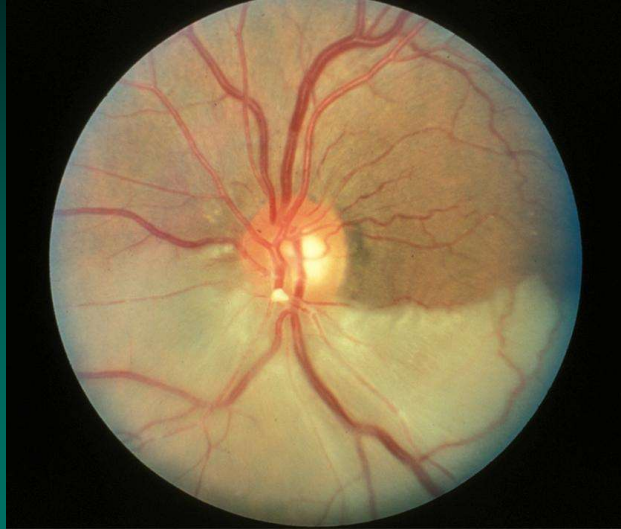
## Hypertensive Retinopathy Hemorrhages, exudates, narrowed arterioles.



ACP  
AMERICAN COLLEGE OF PHYSICIANS  
INTERNAL MEDICINE | Doctors for Adults

24

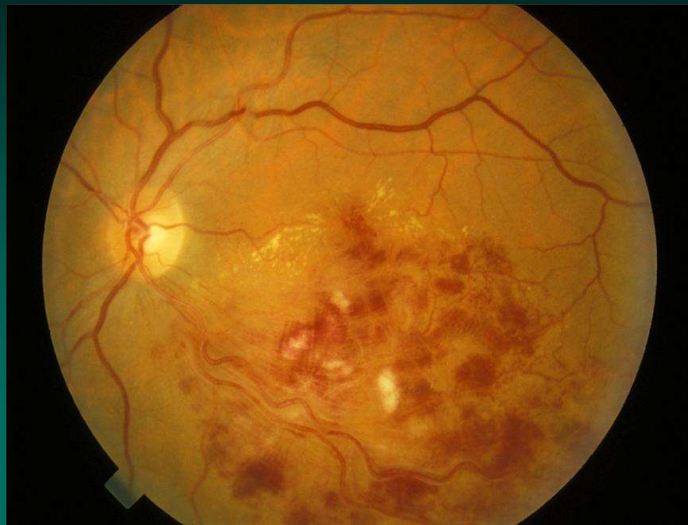
## Branch Retinal Artery Occlusion



ACP  
AMERICAN COLLEGE OF PHYSICIANS  
INTERNAL MEDICINE | Doctors for Adults

25

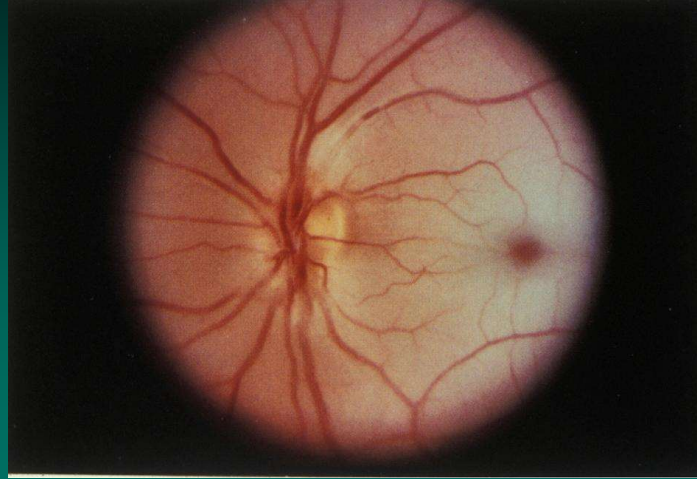
## Branch Retinal Vein Occlusion



ACP  
AMERICAN COLLEGE OF PHYSICIANS  
INTERNAL MEDICINE | Doctors for Adults

26

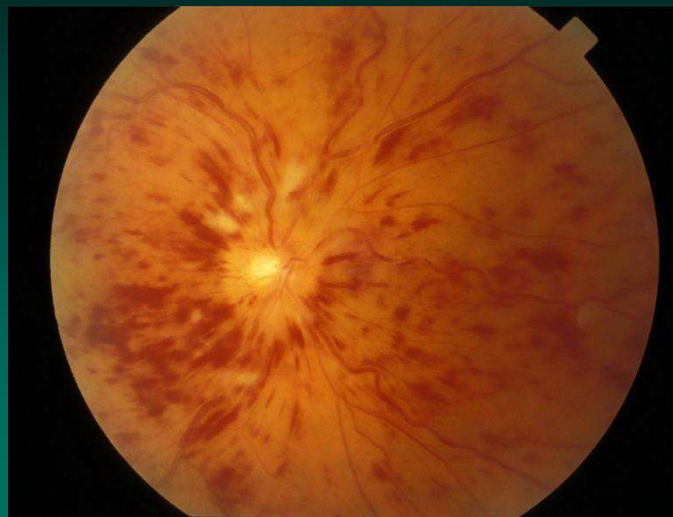
## Central Retinal Artery Occlusion



ACP  
AMERICAN COLLEGE OF PHYSICIANS  
INTERNAL MEDICINE | Doctors for Adults

27

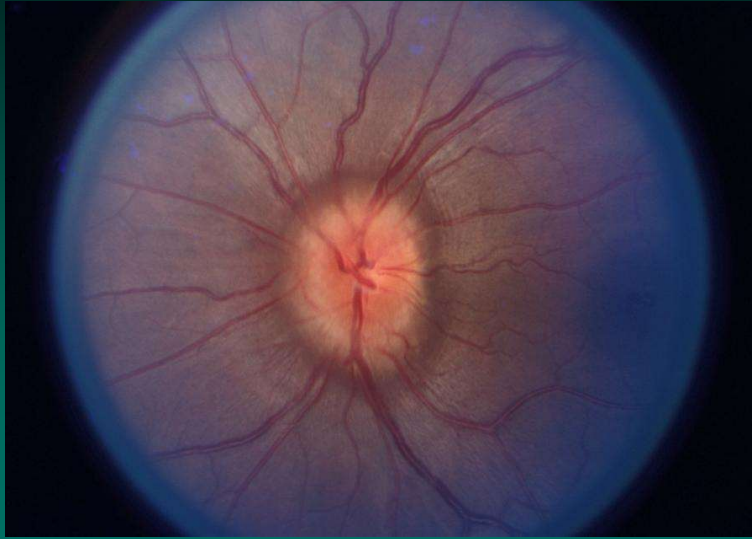
## Central Retinal Vein Occlusion



ACP  
AMERICAN COLLEGE OF PHYSICIANS  
INTERNAL MEDICINE | Doctors for Adults

28

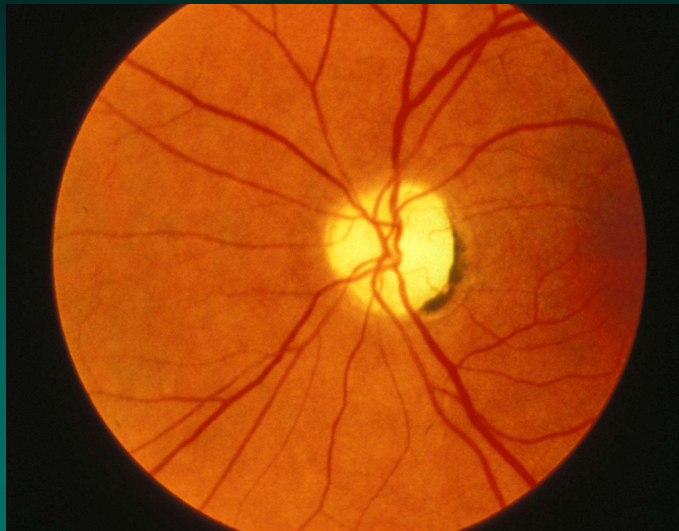
## Disc (papilla) Edema



ACP  
AMERICAN COLLEGE OF PHYSICIANS  
INTERNAL MEDICINE | Doctors for Adults

29

## Optic Disc Atrophy




ACP  
AMERICAN COLLEGE OF PHYSICIANS  
INTERNAL MEDICINE | Doctors for Adults

30



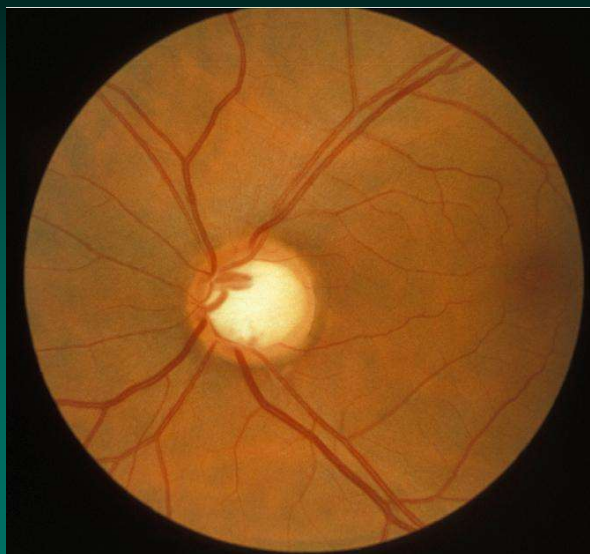
Cup to disc ratio: normal less than 0.5



ACP  
AMERICAN COLLEGE OF PHYSICIANS  
INTERNAL MEDICINE | Doctors for Adults

31

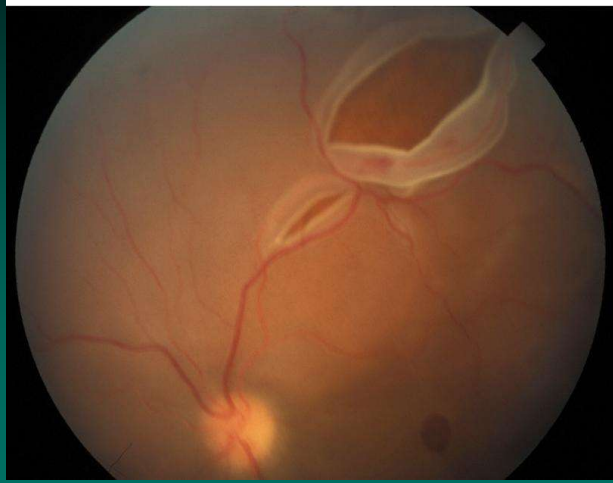
The Glaucomatous Disc  
cup/disc ratio ~ 0.8



ACP  
AMERICAN COLLEGE OF PHYSICIANS  
INTERNAL MEDICINE | Doctors for Adults

32

## Retinal Tear

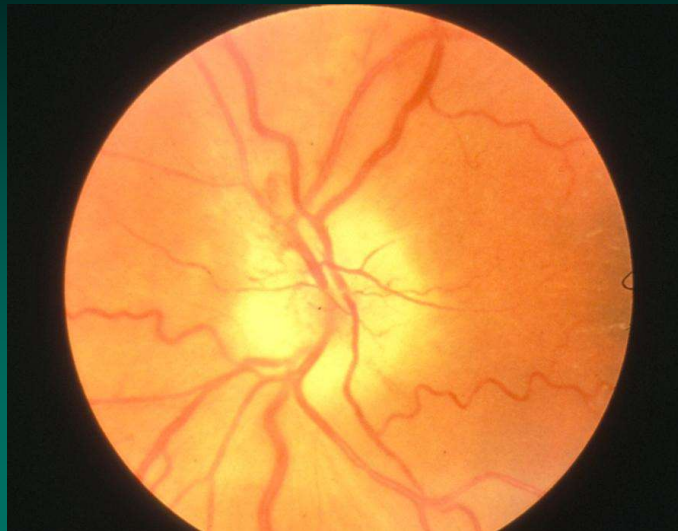


ACP  
AMERICAN COLLEGE OF PHYSICIANS  
INTERNAL MEDICINE | Doctors for Adults

33

## Temporal Arteritis

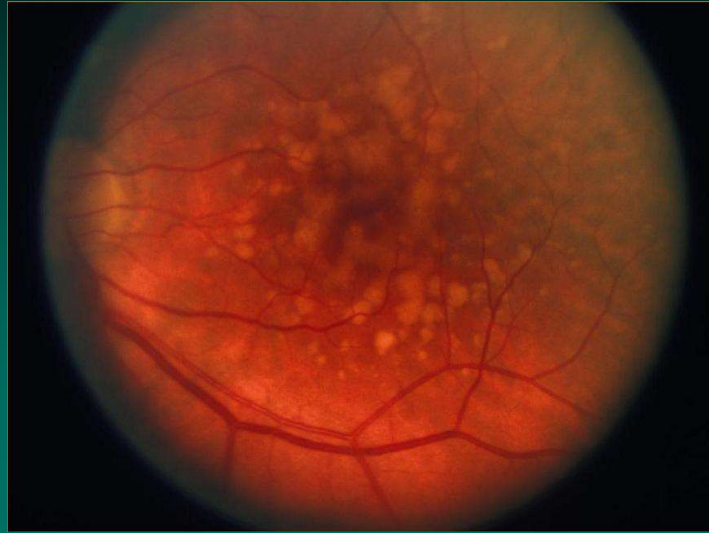
Variable arteriolar diameter and filling, papilledema.



ACP  
AMERICAN COLLEGE OF PHYSICIANS  
INTERNAL MEDICINE | Doctors for Adults

34

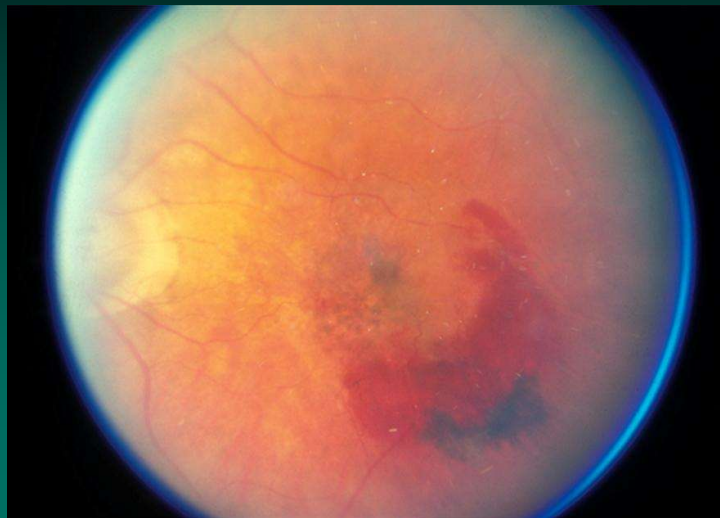
## Age Related Macular Degeneration(Dry)



ACP  
AMERICAN COLLEGE OF PHYSICIANS  
INTERNAL MEDICINE | Doctors for Adults

35

## Age Related Macular Degeneration(Wet)



ACP  
AMERICAN COLLEGE OF PHYSICIANS  
INTERNAL MEDICINE | Doctors for Adults

36